Small bowel capsule endoscopy for the investigation of obscure gastrointestinal bleeding: When we should do it and what should we expect.

Nikos Viazis, Jiannis Anastasiou, Dimitrios G. Karamanolis

Gastroenterology Department, Evangelismos Hospital, Athens – Greece

Abstract

Obscure gastrointestinal bleeding is defined as bleeding of unknown origin that persists or recurs (i.e. recurrent or persistent iron deficiency anemia, fecal occult blood test positivity or visible bleeding) after a negative initial workout that necessarily includes gastroscopy and colonoscopy. In clinical practice, small bowel capsule endoscopy is recommended as a third stage examination in these patients, since it is a simple, safe, non-invasive and reliable test. To date there are three available small bowel capsule systems that have gained FDA approval and their diagnostic yield has shown to be superior to other diagnostic modalities for the investigation of the small bowel in patients with obscure gastrointestinal bleeding. The test should be performed as close to the bleeding episode as possible and the administration of a purgative bowel preparation before the administration of capsule endoscopy is recommended by the European Society of Gastrointestinal Endoscopy (ESGE). Issues that still remain to be solved are the definition of bleeding lesions and what really represents a positive finding, as well as the question of whether the outcome of patients with obscure gastrointestinal bleeding is altered after the test, i.e. to better define subgroups of patients that will mostly benefit from capsule endoscopy. In the future small bowel capsule endoscopy might be able to get guided, while tissue samples might be available as well. (Acta gastroenterol. belg., **2016**, 79, **355-362**).

Definition of obscure gastrointestinal bleeding

Obscure gastrointestinal bleeding (OGIB) is traditionally defined as bleeding of unknown origin that persists or recurs (i.e. recurrent or persistent iron deficiency anemia, fecal occult blood test positivity or visible bleeding) after a negative initial workout including gastroscopy, colonoscopy, small bowel barium follow through or enteroclysis and push enteroscopy (1). Bleeding of obscure origin is further subdivided in two clinical entities: i) Obscure – occult, as manifested by recurrent iron-deficiency anemia and/or recurrent positive fecal occult blood test results, ii) Obscure – overt, with recurrent passage of visible blood (hematochezia / melena) (1). However, it should be noted that according to the American College of Gastroenterology recently published guidelines, it is recommended that the term obscure gastrointestinal bleeding should be reserved for patients in whom a source of bleeding cannot be identified anywhere in the gastrointestinal tract, whereas the term "small bowel bleeding" should be proposed as a replacement for the previous classification of OGIB (2).

Obscure gastrointestinal bleeding and capsule endoscopy

The investigation of obscure gastrointestinal bleeding has been one of the main indications of small bowel capsule endoscopy (CE) in recent years (3). The European Society of Gastrointestinal Endoscopy (ESGE), in its recently published guidelines recommends small bowel video capsule endoscopy as the first line investigation in patients with obscure gastrointestinal bleeding (strong recommendation, moderate quality evidence) (4).

Technical properties of small bowel capsule endoscopy

The capsule endoscope is a disposable, small, swallowable, wireless, miniature camera which allows us to get a direct visualization of the gastrointestinal mucosa. The initial capsule endoscope was developed by Given Imaging (Yoqneam, Israel) and approved in Europe by the European Medicines Agency and in the United States by the Food and Drug Administration (FDA) in 2001 (5). To date this technique is available in over 4500 gastrointestinal centers throughout the world, while four more companies (Olympus Optical Co, Tokyo - Japan.; IntroMedic Company Ltd, Seoul, Korea; Chongqing Jinshan Science and Technology Co, Beijing – China; CapsoVision Inc, Saratoga, CA – U.S.A.) have produced small bowel capsules (6). The five available small bowel capsule systems with their technical properties are presented in table 1.

Is bowel preparation needed before the test?

One of the first studies reporting on this matter published by our group, based on 80 patients, showed that a bowel preparation with 2 liters of polythylene electrolyte solution (PEG), before capsule endoscopy enhanced the diagnostic yield compared with fasting or clear liquid diet (65% vs 40%, p=0.003) (7). Although

Correspondence to : Nikos Viazis, 31st number 11, Elliniko, 16777, Elliniko, Athens-Greece. E-mail: nikos.viazis@gmail.com

Submission date : 29/09/2015
Acceptance date : 29/02/2016

viazis-.indd 355 14/10/16 11:14

Table 1. — **FDA approved small bowel capsule systems**

Name	Company	Size (mm)	Weight (g)	View	Images/sec	Battery life (hours)
Pllcam SB3	Given imaging	11 x 26	3,45	0o	2-6 AFR*	8-14
Endocapsule	Olympus	11 x 26	3,5	145o	2	9
MiroCam	Intromedic	11 x 24	3,3	170o	3	11
OMOM	Chongqing Jinshan	13 x 27,9	6	140o	2	6-8
Capso Vision	CapsoVision Inc	11 x 31	-	360o	3	15

* AFR = Adapted Frame Rate

the question whether bowel preparation is actually needed has been debated by other studies showing no benefit (8,9), a meta-analysis published in 2009 has shown that it is beneficial since we do acquire better images (small bowel visualization quality), achieving an increased diagnostic yield (10).

Based on these reports the European Society of Gastrointestinal Endoscopy (ESGE) guidelines in 2009 recommend the use of purgative bowel preparation since it would enhance the diagnostic yield of small bowel examination during the video capsule endoscopy test (2). As to whether a bowel preparation of 4 liters of PEG would be of added benefit, a meta-analysis has shown that the diagnostic yield of small bowel capsule endoscopy is similar when 2 and 4 liters of purgative solution is used (11). Finally, it should be noted that ingesting a small amount of PEG during and not before the CE procedure has been shown to improve the image quality and completion rate to the cecum (12).

Diagnostic yield of capsule endoscopy in patients with obscure gastrointestinal bleeding

The diagnostic yield of CE in patients with obscure gastrointestinal bleeding has been demonstrated in a number of comparative studies (table 2), which show that capsule endoscopy is superior to push enteroscopy (50-74% vs 19-38%) (13-20), barium follow through (30-55% vs 3-7%) (21-23), computed tomography enteroclysis/enterography (38-78% vs 22-88%) (24-33), intraoperative enteroscopy (74.4% vs 68%) (34,35), double balloon enteroscopy (54-80% vs 56-65%) (36-46) and angiography (53-72% vs 20-56%) (47,48). The diagnostic yield of small bowel capsule endoscopy also appears to be high in the subset of patients with iron deficiency anemia after a negative endoscopic evaluation of the upper and lower gastrointestinal tract (49-52). However, it is of note that not only in the above mentioned studies, but in many others published in the literature, the diagnostic yield of CE in patients with obscure bleeding varies considerably. These immense variations among reports clearly reflect differences in image interpretation, since a consensus on what represents a positive finding has not been reached as yet. According to the classification proposed by Saurin et al (15), lesions found in capsule endoscopy are differentiated to those with an intermediate bleeding potential (P1) and those with a high bleeding potential (P2). According to a classification proposed by our group (53), findings are considered positive if they are the actual source of bleeding, while lesions suspected to be the source are classified as findings of uncertain significance. Using the strict criteria adopted in our classification we reported a diagnostic yield of 41.6% for positive findings in patients subjected to capsule endoscopy for the investigation of obscure gastrointestinal bleeding. The most common positive findings were multiple or

Table 2

Author	Year	Methods	Diagnostic yield
Lewis S, et al	2002	CE vs PE	55% vs 30%
Ell C, et al	2002	CE vs PE	66% vs 28%
Suarin J, et al	2003	CE vs PE	69% vs 38%
Meta A, et al	2004	CE vs PE	74% vs 19%
Triester S et al	2005	CE vs PE	56% vs 26%
deLeusse A, et al	2007	CE vs PE	50% vs 24%
Shidu R, et al	2008	CE vs PE	47% vs 30%
Costamagna G, et al	2002	CE vs BFT	40% vs 20%
Laine L, et al	2010	CE vs BFT	30% vs 7%
Voderholzer et al	2003	CE vs CTE	50% vs 24%
Zhang B, et al	2010	CE vs CTE	72% vs 30%
Auprich J	2011	CE vs CTE	38% vs 88%
Milano et al	2011	CE vs CTE	78% vs 22%
Huprich J, et al	2011	CE vs CTE	38% vs 88%
Khalife S, et al	2011	CE vs CTE	53% vs 34%
Jeon S, et al	2014	CEvs CTE	64% vs 16%
Hartmann D et al	2007	CE vs IOE	74.4% vs 68%
Hadithi M, et al	2006	CE vs DBE	80% vs 60%
Kameda N, et al	2008	CE vs DBE	72% vs 65%
Arakama D, et al	2009	CE vs DBE	54% vs 64%
Teshima C et al	2011	CE vs DBE	62% vs 56%
Shishido T, et al	2012	CE vs DBE	44.9% vs 53.4%
Saperas et al	2011	CE vs ANG	72% VS 56%
Leung W, et al	2012	CE vs ANG	53.3% vs 20%

CE, capsule endoscopy ; PE, push enteroscopy ; BFT, barium follow-through ; CTE, computed tomography enteroclysis/enterography ; DBE, double-balloon enteroscopy ; ANG, angiography

viazis-.indd 356 14/10/16 11:14

bleeding angiodysplasias noted in 56% of the patients (figures 1,2), multiple apthoid ulcerations or mucosal ulcers noted in 25% of patients (figure 3) and bleeding polyps or small bowel tumors noted in 19% of patients (figure 4). These results are in accordance with other studies suggesting that angiodysplasias (50%), ulcers (26.8%) and neoplastic lesions (8.8%) are the most common findings in patients with gastrointestinal bleeding of obscure origin subjected to capsule endoscopy (54) (table 3). However, it has to be noted that despite the abundance of literature data regarding the diagnostic yield of small bowel capsule endoscopy in the setting of bleeding of obscure origin there is still uncertainty among the investigators as of how should they interpret the findings noted. Although multiple angiodysplasias or those actively bleeding could be the bleeding cause, how should diminutive or single angiodysplasias be interpreted by the investigators? How significant is the identification of small erosion or a single aphthoid ulceration? Can a tiny polyp covered with normal-appearing mucosa bleed? Does the mere presence of blood in the small-bowel lumen establish a diagnosis?

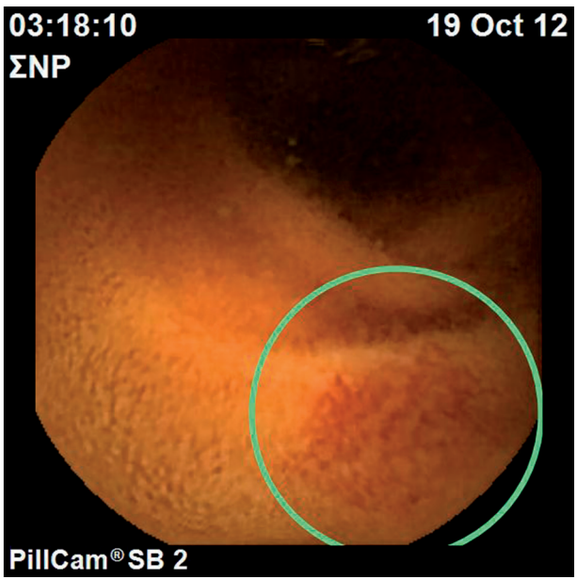

Fig. 1. — Angiodysplasia of the small intestine

Fig. 2. — Actively bleeding angiodysplasia of the small intestine

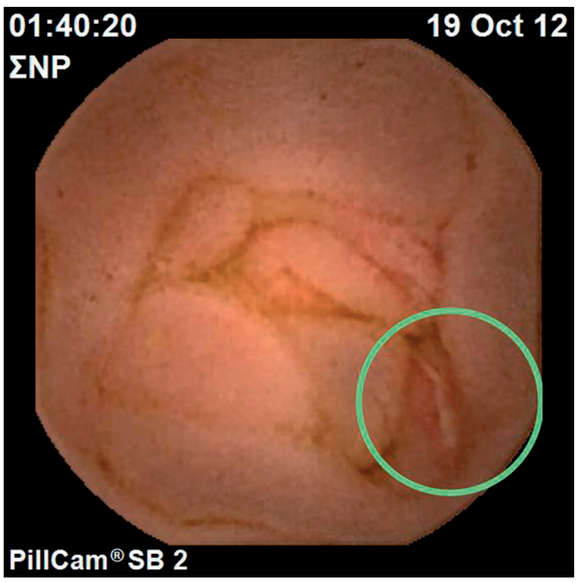

Fig. 3. — Small bowel ulcer

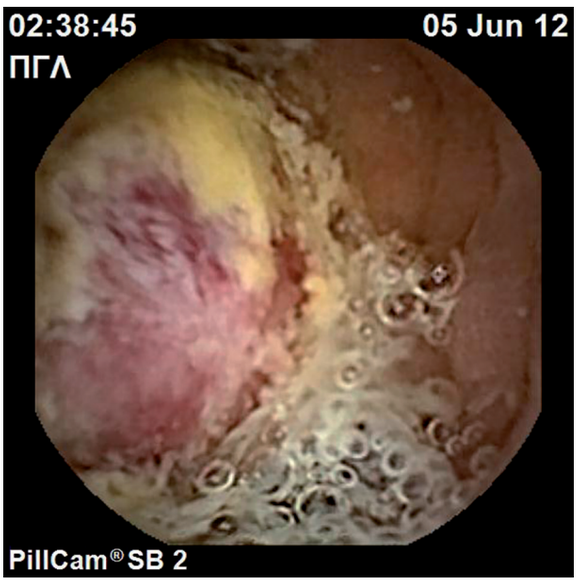

Fig. 4. — Small bowel tumor

viazis-.indd 357 14/10/16 11:14

According to our opinion, findings should be considered positive only if they can actually identify the source of bleeding, while lesions suspected to be the source have to be classified as findings of uncertain significance. The construction of a universal classification with which all investigators could refer to CE findings is eagerly awaited and will definitely be an important advance in the use of this technology.

When is the best timing to perform the test?

In patients with obscure gastrointestinal bleeding, video capsule endoscopy should be performed as soon as possible, i.e as closer to the bleeding episode as possible. According to literature data, the earlier to the onset of the bleeding episode the capsule endoscopy test is performed the greater the diagnostic yield is. Indeed, Pennazio et al reported a significant higher diagnostic yield of video capsule endoscopy in patients with ongoing obscure-overt bleeding (92.3%) as compared to patients with obscure-occult bleeding (44.2%) or patients with a history of obscure-overt bleeding (12.9%) (55). Similar findings were reported by Carey et al, since video capsule endoscopy had a significantly higher diagnostic yield in patients with ongoing bleeding as compared to those with distant overt bleeding (87% vs 56%, p=0.002) (56). Furthermore, in a study by Yamada et al earlier timing of capsule endoscopy achieved a higher diagnostic yield for patients with overt obscure GI bleeding (57), while in another study by Singh et al early deployment of video capsule endoscopy within 3 days of admission resulted in a higher diagnostic yield and therapeutic intervention rate (58).

Does small bowel capsule endoscopy alter the short and long term outcome of patients with obscure gastrointestinal bleeding?

As regards the short term outcome of patients subjected to capsule endoscopy, in the paper by Pennazio et al (55), CE significantly affected outcome in patients with unexplained ongoing overt bleeding; however results were less favorable for patients with previous overt and occult bleeding of obscure origin. In a study by Neu et al (59) 56 patients were followed up for a mean period of 13 months. Outcome change (no further bleeding) was noted in 55% of patients with tumors, erosions or ulcers, in 56% of those with angiodysplasias and in 78% of those with a negative test. As regards the long term outcome, in a trial by Lai et al (60) 49 patients who underwent CE for overt GI bleeding were followed up for a mean period of 19 months. According to this study 58.3% of patients with angiodysplasias and 25% of those with ulcers re-bled, while the re-bleeding rate was 53.8% and 5.6% for those patients with active bleeding and no identifiable cause in CE and those with a negative test respectively. In another trial by our group we reported on the outcome of a substantial number of patients with obscure gastrointestinal bleeding subjected to small bowel capsule endoscopy, after a 2 year follow up period. According to our results CE affected long term outcome in a positive way (i.e. complete resolution of further bleeding) only in those patients with definitive lesions, lesions that can clearly be responsible for the bleeding episode and therefore characterize a diagnostic test (61). As expected definitive lesions are more likely to lead to therapeutic interventions and were finally associated with resolution of bleeding. The same results were reported by Macdonald et al, since during a long term follow up period of 17.3 (±6.2 months) there was a statistically significant difference in rebleeding between patients with positive and patients with a negative study (42% vs 11%, p<0.01) (62).

Despite the undisputable progress in visualizing lesions of the small bowel brought in by CE, a substantial number of patients with OGIB still remain without a diagnosis after the test. The best management of this subset of patients is not known and their management poses a real challenge in clinical practice. Some investigators have suggested that - in cases like these - a second look endoscopy (gastroscopy/colonoscopy) would be of benefit, since studies have shown that up to 30% of lesions suspected to be the cause of bleeding are within the reach of the esophago-gastro-duodenoscope and colonoscope (63-65,). However, such an approach has not been implemented in treatment guidelines and since CE has proven its superiority versus all other tests available for the investigation of the small bowel, one reasonably wanders whether a second CE test would

Table 3. — **Diagnostic yield of capsule endoscopy according to the cause of bleeding**

Pennazio M et al? 2004	Angiodysplasias 24%	Crohn's disease 6%	
Viazis N et al, 2004	Angiodysplasias 56%	Ulcers 25%	Polyps/Tumors 19%
Pasha S et al, 2008	Vascular findings 24%	Inflammatory findings 18%	Polyps/Tumors 11%
Liu K et al, 2011	Angiodysplasias 50%	Ulcers 26,8%	Neoplastic lesions 8,8%
Tenembaum D et al, 2013	Angioectasias 25%	Polyps 22%	Small bowel diverticula 1%

viazis-.indd 358 14/10/16 11:14

benefit these patients. According to the results reported in our latter study (61), there is a subgroup of this population that will indeed benefit from a second look capsule endoscopy. This subgroup consists of patients whose presentation changed from occult to overt and those with a drop in hemoglobin 4g/dL or more. We can therefore suggest that patients with OGIB and a non diagnostic first CE should be spared from further invasive testing and energies should be redirected toward the best option, namely a second look CE, only if they present for the first time with an overt bleeding episode (hematochezia/melena) or if they drop their hemoglobin by at least 4g/dL. Management of the remaining patients is unfortunately considered problematic and further studies should be carried out in order to identify the best diagnostic algorithm that need to be followed. Although it is logical for one to wander why bleeding lesions seen on the second look capsule endoscopy were missed by the first test, no certain explanation can be given. Could it be that as CE propels itself through the small intestine certain areas of the jejunal or ileal mucosa are not seen? This is a logical explanation, albeit difficult to be proven. Could it be that lesions in the terminal ileum are missed in cases that CE does not reach the cecum during the life span of its battery? This was indeed the case in certain instances; however incomplete visualization of the small intestine was not a predictive factor of a diagnostic second look capsule endoscopy test. Could it be that certain lesions, such as angiodysplasias are not bleeding at the time of the CE and therefore are not seen? This is also a plausible explanation, since angiodysplasias of the small intestine were the commonest finding during the second look CE and it can be hypothesized that they were not bleeding "enough" during the first test in order to be visualized. The fact that only patients with a significant drop in hemoglobin or those whose bleeding presentation changed from occult to overt had a diagnostic second look test, theoretically could give some support to the above hypothesis. To further support our hypothesis that lesions can be missed during the first capsule test, a study by Triantafyllou et al investigated the added benefit of dual head capsule (Pillcam Colon Given Imaging, Yoqneam, Israel) in patients investigated for small bowel pathology. The study revealed that each dual head camera misses 40% of the significant findings and 30% of the findings of uncertain significance detected by the other one. The authors state, that although it is not clear why this happens, one possible explanation could be that because the capsule endoscope is trembling and rotating in the small bowel lumen, there might be blind spots along its passage that can be detected on a second camera recording (66).

Several studies have also tried to identify predictors of rebleeding in patients subjected to capsule endoscopy for the investigation of obscure gastrointestinal bleeding. In a recent publication by Canas-Ventura et al, one third of the patients presented with rebleeding after CE; risk factors were hemoglobin levels < 8 g/dL, age ≥ 70 years or the presence of significant lesions (67). Furthermore, in a Japanese study cox hazard regression analysis revealed that advanced age was a predictive factor for re-bleeding after a negative capsule endoscopy (68), while in another study angiodysplasias and duration of obscure gastrointestinal bleeding > 3 months were independent prognostic factors associated with re-bleeding (69). Finally in two recent studies the use of anticoagulants, antiplatelet or non-steroidal anti-inflammatory drugs after CE were independent risk factors associated with rebleeding (70), while the same was true for angiodysplasia and duration of OGIB >3 months (71).

Of course, double-balloon enteroscopy, CT or MR enterography should also be considered in patients with a negative capsule endoscopy when clinical

suspicion for small bowel pathology persists. Indeed, in a study by Postgate et al significant small bowel pathology (adenocarcinoma, malignant melanoma, varices, stromal tumor and Peutz-Jeughers syndrome polyp) was missed at capsule endoscopy in 5 patients, but was subsequently detected by alternative modalities (72).

Limitations and contraindications of small bowel capsule endoscopy

The retention of capsule endoscopy is the main complication of the procedure and is defined when the device remains in the digestive tract for a minimum of 2 weeks (73). The frequency of this problem varies and ranges from 0% in healthy subjects, to 1.5% in patients with obscure gastrointestinal bleeding (74), controlled remotely. CE has also some clinical limitations which are problems in sizing and locating small bowel lesions.

Conclusion and future directions

Management of patients with gastrointestinal bleeding of obscure origin remains a challenging problem in clinical practice. When a bleeding source is not identified in upper or lower GI endoscopy, the small bowel is interrogated and wireless capsule endoscopy has become the method of choice for this purpose. In the future CE may be used to determine medical response to therapy, while new capsules might be able to be controlled remotely, to provide tissue for histological examination in addition to improved views and extended battery life for visualization of the entire small intestine (78,79). These changes would help us identify more lesions in patients subjected to the test for the investigation of small bowel bleeding and therefore increase the diagnostic yield of capsule endoscopy in this main indication. Moreover, the use of devices for SBCE equipped with more than one camera, with lateral viewing, with digital chromoendoscopy and high definition imaging might be a reality in the years to come (80). Indeed, a magnetically guided capsule endoscopy has been developed jointly

viazis-.indd 359 14/10/16 11:14

by Olympus Medical Systems Corporation and Siemens Healthcare and has already been tested versus high definition gastroscopy in a comparative study of 85 patients with a clinical indication for gastric examination with promising results (81). Future projects also include the NEMO and VECTOR capsules. A consortium funded by the European Union, worked on NEMO (Nano based capsule-Endoscopy with Molecular Imaging and Optical biopsy) project, with main aim to combine capsule endoscopy with nano-based molecular recognition that would highlight cancerous and precancerous lesions in the GI tract (82). Versatile Endoscopy Capsule for gastrointestinal TumOr Recognitions and therapy (VECTOR) is another project funded by the European Union, aiming to develop a miniaturized robotic wireless endoscope for both diagnosis and therapy in the human digestive tract, with particular focus on the diagnosis and treatment of gastrointestinal cancer and its precursors (83). Results on clinical trials regarding these projects are eagerly awaited.

Do's and Don'ts for small bowel capsule endoscopy

1. Small bowel capsule endoscopy should be the first-line investigation in patients with obscure gastrointestinal bleeding after a negative upper and lower gastrointestinal endoscopy

2. Do capsule endoscopy as close to the bleeding episode as possible

3. Do double balloon enteroscopy in patients with positive findings in capsule endoscopy

4. Don't routinely perform a second look endoscopy before capsule endoscopy in patients with obscure gastrointestinal bleeding or iron deficiency anaemia.

References

1. RAJU G.S., GERSON L., DAS A., LEWIS B. American Gastroenterological Association. American Gastroenterological Association (AGA) Institute medical position statement on obscure gastrointestinal bleeding. *Gastroenterology*, 2007 Nov., **133(5)** : 1694-6
2. GERSON L., FIDLER J., CAVE D., LEIGHTON J. ACG Clinical Guideline: Diagnosis and management of small bowel bleeding. *Am. J. Gastroenterol.*, 2015, **110** : 1265-87.
3. LADAS S., TRIANTAFYLLOU K., SPADA C., RICCIONI M. *et al*. European Society of Gastrointestinal Endoscopy (ESGE): Recommendations (2009) on clinical use of video capsule endoscopy to investigate small-bowel, esophageal and colonic diseases. *Endoscopy*, 2010, **42(3)** : 220-227
4. PENNAZIO M., SPADA C., ELIAKIM R. *et al*. Small bowel capsule endoscopy and device-assisted enteroscopy for diagnosis and treatment of small bowel disorders: European Society of Gastrointestinal Endoscopy (ESGE) clinical guideline. *Endoscopy*, 2015, **47** : 352-76.
5. IDDAN G., MERON G., GLUKHOVSKY A., SWAIN P. Wireless capsule endoscopy. *Nature*, 2000, **405** : 417.
6. WANG A., BANERJEE S., BARTH B.A. *et al*. Wireless capsule endoscopy. ASGE Technology Committee. *Gastrointest. Endosc.*, 2013 Dec, **78(6)** : 805-15.
7. VIAZIS N., SGOUROS S., PAPAXOINIS K. *et al*. Bowel preparation increases the diagnostic yield of capsule endoscopy : a proespecive, randomised, controlled study. *Gastrointest. Endosc.*, 2004, **60(4)** : 534-538.
8. VAN TUYL S., DEN OUDEN H., STOLK M., KUIPERS E. Optimal preparation for video capsule endoscopy. A prospective, randomized, single blind study. *Endoscopy*, 2007, **39** : 1037-40.
9. PARK S., KEUM B., SEO Y. *et al*. Effect of bowel preparation with polyethylene glycol on quality of capsule endoscopy. *Dig. Dis. Sci.*, 2011, **56** : 1769-1775.
10. ROKKAS T., PAPAXOINIS K., TRIANTAFYLLOU K., PISTIOLAS D., LADAS S.D. Does purgative preparation influence the diagnostic yield of small bowel video capsule endoscopy ? A meta-analysis. *Am. J. Gastroenterol.*, 2009 Jan, **104(1)** : 219-27.
11. SONG H., MOON J., HYUK D. *et al*. Guidelines for bowel preparation before video capsule endoscopy. *Clin. Endosc.*, 2013, **46(2)** : 147-154.
12. ENDO H., KONDO Y., INAMORI M. *et al*. Ingesting 500 ml of polyethylene glycol solution during capsule endoscopy improves the image quality and completion rate to the cecum. *Dig. Dis. Sci.*, 2008, **53** : 3201-3205.
13. LEWIS B., SWAIN P. Capsule endoscopy in the evaluation of patients with suspecteded small intestinal bleeding. Results of a pilot study. *Gastrointest. Endosc.*, 2002, **56(3)** : 342-53.
14. ELL C., REMKE S., MAY A., HELOU L., HENRICH R., MEVER G. The first prospective controlled trial comparing wireless capsule endoscopy with push enteroscopy in chronic gastrointestinal bleeding. *Endoscopy*, 2002, **34(9)** : 685-9.
15. SAURIN J., DELVAUZ M., GAUDIN J. *et al*. Diagnostic value of endoscopic capsule in patients with obscure digestive bleeding: blinded comparison with video push enteroscopy. *Endoscopy*, 2003, **35(7)** : 576-84.
16. META A., BARDAS J., FEU F. *et al*. Wireless capsule endoscopy in patients with obscure gastrointestinal bleeding: a comparative study with push enteroscopy. *Aliment. Pharmacol. Ther.*, 2004, **20(20)** : 189-94.
17. TRIESTER S., LEIGHTON J., LEONTIADIS G. *et al*. A meta-analysis of the yield of capsule endoscopy compared to other diagnostic modalities in patients with obscure gastrointestinal bleeding. *Am. J. Gastroenterol.*, 2005, **100** : 2407-18.
18. PENNAZIO M., ARRIGONI A., RISIO M. *et al*. Clinical evaluation of push-type enteroscopy. *Endoscopy*, 1995, **27** : 164-70.
19. SIDHU R., MCALINDON M., KAPUR K. *et al*. Push enteroscopy in the era of capsule endoscopy. *J. Clin. Gastroenterol.*, 2008, **42** : 54-8.
20. DE LEUSSE A., VAHEDI K., EDERY J. *et al*. Capsule endoscopy or push enteroscopy for first line exploration of obscure gastrointestinal bleeding. *Gastroenterology*, 2007, **132** : 855-62.
21. COSTAMAGNA G., SHAH S., RICCIONI M. *et al*. A prospective trial comparing small bowel radiographs and video capsule endoscopy for suspected small bowel disease. *Gastroenterology*, 2002, **123(4)** : 999-1005.
22. HARA A., LEIGHTON J., SHARMA E. *et al*. Small bowel : preliminary comparison of capsule endoscopy with barium study and CT. *Radiology*, 2004, **230** : 260-65.
23. LAINE L., SAHOTA A., SHAH A. *et al*. Does capsule endoscopy improve outcomes in obscure gastrointestinal bleeding: Randomized trial versus dedicated small bowel radiography. *Gastroenterology*, 2010, **138** : 1673-80.
24. VODERHOLZER W., BEINHOELZL J., ROGALLA P. *et al*. Diagnostic yield of wireless capsule enteroscopy in comparison with computed tomography enteroclysis. *Endoscopy*, 2003, **35** : 1009-1014.
25. ZHANG B., JIANG L., CHEN X., ZHONG B., LI Y. Diagnosis of obscure gastrointestinal hemorrhage with capsule endoscopy in combination with multiple-detector computed tomography. *J. Gastroenterol. Hepatol.*, 2010, **25(1)** : 75-9.
26. AUPRICH J., FLETCHER J., FIDLER J. *et al*. Prospective blinded comparison of wireless capsule endoscopy and multiphase CT enterography in obscure gastrointestinal bleeding. *Radiology*, 2011, **260(3)** : 744-51.
27. MILANO A., BALATSINOU C., FILIPPONE A. *et al*. A prospective evaluation of iron deficiency anemia in the GI endoscopy setting: role of standard endoscopy, videocapsule endoscopy and CT-enteroclysis. *Gastrointest. Endosc.*, 2011, **73** : 1002-8.
28. JEON S., JIN-OH K., GUN K. *et al*. Is there a difference between capsule endoscopy and computed tomography as a first line study in obscure gastrointestinal bleeding ? Turk. *J. Gastroenterol.*, 2014., **25(3)** : 257-63.
29. HUPRICH J., FLETCHER J., FIDLER J. *et al*. Prospective blinded comparison of wireless capsule endoscopy and multiphase CT enterography in obscure gastrointestinal bleeding. *Radiology*, 2011, **260** : 744-51
30. RAJESH A., SANDRASEGARAN K., JENNINGS S. *et al*. Comparison of capsule endoscopy with enteroclysis in the investigation of small bowel disease. *Abdom. Imaging*, 2009, **34** : 459-66.
31. KHALIFE S., SOYER P., ALATAWI A. *et al*. Obscure gastrointestinal bleeding: preliminary comparison of 64-section CT enteroclysis with video capsule endoscopy. *Eur. Radiol.*, 2011, **21** : 79-86.
32. VODERHOLZER W., ORTNER M., ROGALLA P. *et al*. Diagnostic yield of wireless capsule enteroscopy in comparison with computed tomography enteroclysis. *Endoscopy*, 2003, **35** : 1009-14.
33. AGRAWAL J., TRAVIS A., MORTELE K. *et al*. Diagnostic yield of dual phase computed tomography enterography in patients with obscure

viazis-.indd 360 14/10/16 11:14

gastrointestinal bleeding and a non-diagnostic capsule endoscopy. *J. Gastroenterol. and Hepatol.*, 2012, **27** : 751-59.
34. HARTMANN D., SCHMIDT H., BALZ G. *et al*. A prospective two-center study comparing wireless capsule endoscopy with intraoperative enteroscopy in patients with obscure GI bleeding. *Gastrointest. Endosc.*, 2005, **61(7)** : 826-32.
35. HARTMANN D., SCHMIDT H., SCHILLING D. *et al*. Follow-up of patients with obscure gastrointestinal bleeding after capsule endoscopy and intraoperative enteroscopy. *Hepatogastroenterology*, 2007, **54** : 780-783.
36. NAKAMURA M., NIWA Y., OHMIYA M. *et al*. Preliminary comparison of capsule endoscopy and double-balloon enteroscopy in patients with suspected small-bowel bleeding. *Endoscopy*, 2006, **38** : 59-66.
37. HADITHI M., HEINE G., JACOBS M., VAN BODEGRAVEN A., MULDER C. A prospective study comparing video capsule endoscopy with double-balloon enteroscopy in patients with obscure gastrointestinal bleeding. *Am. J. Gastroenterol.*, 2006, **101(1)** : 52-7.
38. KAMEDA N., HIGUCHI K., SHIBA M. *et al*. A prospective single blind trial comparing wireless capsule endoscopy and double balloon enteroscopy in patients with obscure gastrointestinal bleeding. *J. Gastroenterol.*, 2008, **43(6)** : 434-40.
39. ARAKAMA D., OHMIYA N., NAKAMURA M. *et al*. Outcome after enteroscopy for patients with obscure GI bleeding: diagnostic comparison between double balloon endoscopy and video capsule endoscopy. *Gastrointest. Endosc.*, 2009, **69(4)** : 866-74
40. TESHIMA C., KUIPERS E., VAN ZANTEN S. *et al*. Double balloon enteroscopy and capsule endoscopy for obscure gastrointestinal bleeding: an updated meta-analysis. *J. Gastroenterol. Hepatol.*, 2011, **26** : 796-801.
41. RAHMI G., SAMAHA E., VAHED K. Long term follow up of patients undergoing capsule endoscopy and double-balloon enteroscopy for identification and treatment of small bowel vascular lesions. A prospective, multi-center study. *Endoscopy*, 2014, **46(7)** : 591-7.
42. TENEMBAUM D., SISON C., RUBIN M. *et al*. Accuracy of community based video capsule endoscopy in patients undergoing follow up double balloon enteroscopy. *World J. Gastrointest. Endosc.*, 2013, **5** : 154-9.
43. SHISHIDO T., OKA S., TANAKA S. *et al*. Diagnostic yield of capsule endoscopy vs double balloon endoscopy for patients who have undergone total enteroscopy with obscure gastrointestinal bleeding. *Hepatogastroenterology*, 2012, **59** : 955-59.
44. PASHA S., LEIGHTON J., DAS A. *et al*. Double balloon enteroscopy and capsule endoscopy have comparable diagnostic yield in small bowel disease: a meta-analysis. *Clin. Gastroenterol. Hepatol.*, 2008, **6** : 671-6.
45. CHEN X., RAN Z., TONG J. A meta-analysis of the yield of capsule endoscopy compared to double balloon enteroscopy in patients with small bowel disease. *World J. Gastroenterol.*, 2007, **13** : 4372-78.
46. WIARDA B., HEINE D., MENSINK P. *et al*. Comparison of magnetic resonance enteroclysis and capsule endoscopy with balloon assisted enteroscopy in patients with obscure gastrointestinal bleeding. *Endoscopy*, 2012, **44** : 668-73.
47. SAPERAS E., DOT J., VIDELA J. *et al*. Capsule endoscopy versus computed tomographic or standard angiography for the diagnosis of obscure gastrointestinal bleeding. *Am. J. Gastroenterol.*, 2007, **102** : 731-737.
48. LEUNG W., HO S., SUEN B. *et al*. Capsule endoscopy or angiography in patients with acute overt obscure gastrointestinal bleeding: a prospective randomized study with long term follow up. *Am. J. Gastroenterol.*, 2012, **107** : 1370-76.
49. APOSTOLOPOULOS P., LIATSOS C., GRANLEK I. *et al*. The role of wireless capsule endoscopy in investigating unexplained iron deficiency anemia after negative endoscopic evaluation of the upper and lower gastrointestinal tract. *Endoscopy*, 2008, **38(11)** : 1127-32.
50. RICCIONI M., URGESI R., SPADA C. *et al*. Unexplained iron deficiency anaemia: is it worthwhile to perform capsule endoscopy ? *Dig. Liver Dis.*, 2010, **42(8)** : 560-6.
51. HOLLERAN G., BARRY S., THORNTON G., DOBSAN M., MCNAMARA D. The use of small bowel capsule endoscopy in iron deficiency anemia: low impact in outcome in the medium term, despite high diagnostic yield. Eur J *Gastroenterol. Hepatol.*, 2013, **25(3)** : 327-32.
52. KOULAOUZIDIS A., YUNG D., LAM J., SMIRNIDIS A., DOUGLAS S., PLEVRIS J. The use of small bowel capsule endoscopy in iron deficiency anemia alone; be aware of the young anemic patient. *Scand. J. Gastroenterol.*, 2012, **47(8-9)** : 1094-100.
53. VIAZIS N., PAPAXOINIS K., THEODOROPOULOS I. *et al*. Impact of capsule endoscopy in obscure small bowel bleeding: defining strict diagnostic criteria for a favorable outcome. *Gastrointest. Endosc.*, 2005 Nov., **62(5)** : 717-22.
54. LIU K., KAFFES A. Review article: the diagnosis and investigation of obscure gastrointestinal bleeding. *Aliment. Pharmacol. Ther.*, 2011, **34(4)** : 416-23.
55. PENNAZIO M., SANTUCCI R., RONDONOTTI E. *et al*. Outcome of patients with obscure gastrointestinal bleeding after capsule endoscopy: Report of 100 consecutive cases. *Gastroenterology*, 2004, **126** : 643-653.
56. CAREY E., LEIGHTON J., HEIGH R. *et al*. A single-center experience of 260 consecutive patients undergoing capsule endoscopy for obscure gastrointestinal bleeding. *Am. J. Gastroenterol.*, 2007, **102(1)** : 89-95.
57. YAMADA A., WATABE H., KOBAYASHI K. *et al*. Timing of capsule endoscopy influences the diagnosis and outcome in obscure-overt gastrointestinal bleeding. *Hepatogastroenterology*, 2012, **59(115)** : 676-9.
58. SINGH A;, MARSHALL C., CHAUDHURI B. *et al*. Timing of video capsule endoscopy relative to overt obscure GI bleeding : implications from a retrospective study. *Gastrointest. Endosc.*, 2013, **77(5)** : 761-6.
59. NEU B., ELL C., MAY A. *et al*. Capsule endoscopy versus standard tests in influencing management of obscure digestive bleeding: Results from a German Multicenter Trial. *Am. J. Gastroenterol.*, 2005, **100** : 1736-1742.
60. LAI L., WONG G., CHOW D. *et al*. Long term follow up of patients with obscure gastrointestinal bleeding after negative capsule endoscopy. *Am. J. Gastroenterol.*, 2006, **101** : 1224-1228.
61. VIAZIS N., PAPAXOINIS K., VLACHOGIANNAKOS J., EFTHYMIOU A., IOANNIS THEODOROPOULOS I., KARAMANOLIS D. Is there a role for second look capsule endoscopy in patients with obscure gastrointestinal bleeding after a non diagnostic first test ? *Gastrointest. Endosc.*, 2009 Apr., **69(4)** : 850-6.
62. MACDONALD J., PORTER V., MCNAMARA D. *et al*. Negative capsule endoscopy in patients with obscure GI bleeding predicts low rebleeding rates. *Gastrointest. Endosc.*, 2008, **68** : 1122-27.
63. ELIJAH D., DOAS A., BRADY P. Capsule endoscopy for obscure GI bleeding yields a high incidence of significant treatable lesions within reach of standard upper endoscopy. *J. Clin. Gastroenterol.*, 2008, **42(8)** : 962-3.
64. VLACHOGIANNAKOS J., PAPAXOINIS K., VIAZIS N. *et al*. Bleeding lesions within reach of conventional endoscopy in capsule endoscopy examinations for obscure gastrointestinal bleeding: is repeating endoscopy economically feasible ? *Dig. Dis. Sci.*, 2011, **56(6)** : 1763-8.
65. GILBERT D., O'MALLEY S., SELBY W. *et al*. Are repeat upper gastrointestinal endoscopy and colonoscopy necessary within 6 months of capsule endoscopy in patients with obscure gastrointestinal bleeding ? *J. Gastroenterol. Hepatol.*, 2008, **23** : 1806-9.
66. TRIANTAFYLLOU K., PAPANIKOLAOU S., PAPAXOINIS K., LADAS S.D. Two cameras detect more lesions in the small-bowel than one. *World J. Gastroenterol.*, 2011, **17(11)** : 1462-7.
67. CANAS-VENTURA A., MARQUEZ L., BESSA X. *et al*. Outcome in obscure gastrointestinal bleeding after capsule endoscopy. *World J. Gastrointest. Endosc.*, 2013, **5(11)** : 551-8.
68. MATSUMURO T., ARAI M., SAITO K. *et al*. Predictive factors of re-bleeding after negative capsule endoscopy for obscure gastrointestinal bleeding : over 1-year follow up study. *Dig. Endosc.*, 2014, Mar 13. doi : 10.1111/den:12257.
69. MIN Y., KIM J., JEON S. *et al*. Long term outcome of capsule endoscopy in obscure gastrointestinal bleeding: a nationwide analysis. *Endoscopy*, 2014, **46(1)** : 59-65.
70. TAN W., GE Z., GAO Y. *et al*. Long-term outcome in patients with obscure gastrointestinal bleeding after capsule endoscopy. *J. Dig. Dis.*, 2015, **16(3)** : 125-34.
71. MIN Y., KIM J., JEON S. *et al*. Long-term outcome of capsule endoscopy in obscure gastrointestinal bleeding : a nationwide analysis. *Endoscopy*, 2014, **46(1)** : 59-65.
72. POSTGATE A., DESPOTT E., BURLING D. *et al*. Significant small-bowel lesions detected by alternative diagnostic modalities after negative capsule endoscopy. *Gastrointestin. Endosc.*, 2008, **68(6)** : 1209-14.
73. CAVE D., LEGNANI P., DE FRANCHIS R., LEWIS B.S. ICCE consensus for capsule retention. *Endoscopy*, 2005, **37** : 1065-1067.
74. SHIM K., MOON J., CHANG D. *et al*. Guideline for capsule endoscopy : obscure gastrointestinal bleeding. *Clin. Endosc.*, 2013, **46** : 45-53.
75. BANDORSKI D., IRNICH W., BRÜCK M. et al. Capsule endoscopy and cardiac pacemakers: investigation for possible interference. *Endoscopy*, 2008, **40** : 36-39.
76. LEIGHTON J., SRIVATHSAN K., CAREY E. *et al*. Safety of wireless capsule endoscopy in patients with implantable cardiac defibrillators. *Am. J. Gastroenterol.*, 2005, **100** : 1728-31.
77. LIAO Z., GAO R., XU C. *et al*. Indications and detection, completion and retention rates of small bowel capsule endoscopy : a systematic review. *Gastrointest. Endosc.*, 2010, **71** : 280-86.
78. SWAIN P. The future of wireless capsule endoscopy. *World J. Gastroenterol.*, 2008, **14** : 4142-4145.
79. REY J. The future of capsule endoscopy. *Keio J. Med.*, 2013, **62(2)** : 41-46.

viazis-.indd 361 14/10/16 11:14

80. KOULAOUZIDIS A., IAKOVIDIS D., KARARGYRIS A., RONDONOTTI E. Wireless endoscopy in 2020 : Will it still be a capsule ? *World J. Gastroenterol*. 2015, **21(17)** : 5119-30.
81. REY J., OGATA H., HOSOE N. *et al*. Blinded nonrandomized comparative study of gastric examination with a magnetically guided capsule endoscope and standard videoendoscope. *Gastrointest. Endosc*., 2012, 75 : 373-81.
82. Nano based capsule-Endoscopy with Molecular Imaging and Optical biopsy project. Available from: http://fcs.itc.it/NEMO
83. Versatile endoscopy capsule for gastrointestinal tumor recognitions and therapy. Available from : http://www.vector-project.com

viazis-.indd 362 14/10/16 11:14